

# First Report of a *Troglostrongylus brevior* Case in a Domestic Cat in Turkey

## *Evcil Kedilerde Troglostrongylus brevior: Türkiye'deki İlk Olgu*

Şinasi Umur, Öykü Barılı, E. Burcu Gencay Topçu, Ali Tümay Gürler

Ondokuz Mayıs University Faculty of Veterinary Medicine, Department of Parasitology, Samsun, Turkey

Cite this article as: Umur Ş, Barılı Ö, Gencay Topçu EB, Gürler AT. First Report of a *Troglostrongylus brevior* Case in a Domestic Cat in Turkey. Türkiye Parazitol Derg 2020;44(3):176-8.

### ABSTRACT

Parasitic bronchopneumonia plays an important role, especially in the respiratory diseases of cats. *Troglostrongylus* species have been reported as lung parasites of wild cats; however, in recent years, they have also been found in domestic cats, especially from the Mediterranean and Balkan countries. In this report, *Troglostrongylus brevior* was found during the examination of lung samples of a tabby cat who was euthanized at the age of 2 years. To the best of our knowledge, this is the first report of *Troglostrongylus brevior* in Turkey.

**Keywords:** *Troglostrongylus brevior*, cat, feline lungworms, nematode, Turkey

### ÖZ

Kedilerin solunum sistemi hastalıklarında parazitik bronkopneumoni önemli rol oynar. *Troglostrongylus* türleri yabani kedilerde bulunmasına karşın, son yıllarda özellikle Akdeniz ve Balkan ülkelerinde evcil kedilerde de sık rastlanmaktadır. Bu olguda, hastalığa bağlı ötenazi uygulanan iki yaşlı evcil kedinin akciğer dokusunda rastlanan *Troglostrongylus brevior* rapor edilmiştir. Bilgilerimize göre Türkiye'de ilk *Troglostrongylus brevior* olgusudur.

**Anahtar kelimeler:** *Troglostrongylus brevior*, kedi, akciğer kılkurdu, nematod, Türkiye

### INTRODUCTION

Among the parasitic factors leading to respiratory diseases in cats, *Aelurostrongylus abstrusus* comes first, but publications on the *Troglostrongylus* species have also increased in recent years (1).

There are *Troglostrongylus brevior*, *T. subcrenatus*, *T. troglostrongylus*, and *T. wilsoni* species in the Metastrongyloidea superfamily, and they are frequently seen in wild felines (2). In recent years, due to the increase of environmental protection awareness, the wild cat population has increased and their contact with domestic cats has also increased. Therefore, many parasites in the wild cats have begun to appear in domestic cats.

In the present study, detailed information was given about the parasite.

### CASE REPORT

A 2-year-old female tabby cat admitted to a private veterinary clinic with the complaints of weakness, anorexia, vomiting, and high fever in Bodrum district, Muğla. Hemogram showed lymphopenia, neutropenia, and thrombocytopenia. In the first two days, supportive treatment was applied to the cat, but the result was unsuccessful. On the 3<sup>rd</sup> day, icterus started, and on the 4<sup>th</sup> day, fluid accumulation occurred in the abdominal and thoracic cavities. Rapid diagnostic test kit for the Coronavirus was positive as well as Rivalta test performed on abdominal effusion obtained from the cat. Therefore, it was decided to be euthanized.

Formalin fixed lung sample sent to the parasitology laboratory was examined under a stereomicroscope and round parasites were found in the bronchi



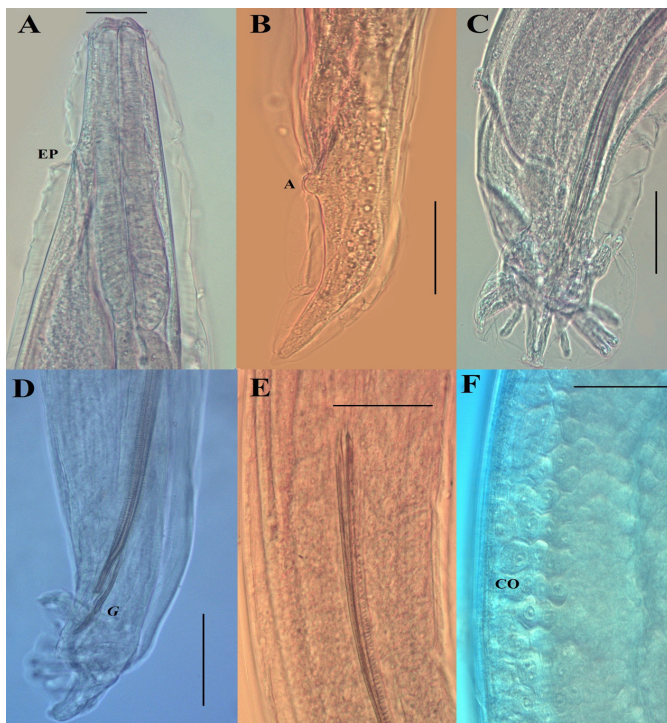
Received/Geliş Tarihi: 06.04.2020 Accepted/Kabul Tarihi: 08.05.2020

Address for Correspondence/Yazar Adresi: Şinasi Umur, Ondokuz Mayıs University Faculty of Veterinary Medicine, Department of Parasitology, Samsun, Turkey

Phone/Tel: +90 532 658 38 26 E-mail/E-Posta: sumur@omu.edu.tr ORCID ID: orcid.org/0000-0001-9766-2817

and bronchioles. Parasites were removed from the lungs, then cleaned and clarified in lactophenol. They were identified based on the literatures (3,4). Important morphological regions were measured during the diagnosis and photographed. Polymerase chain reaction was performed to molecularly confirm the specific diagnosis of the parasite, but no results were obtained because the tissue was transported in 10% formalin. Voucher specimens were deposited in the Helminth Coll. OMUPAR.12.19.11 Department of Parasitology, Faculty of Veterinary Medicine, Samsun, Turkey.

In the bronchi and bronchioles, a total of three parasites were found; two males and one female. The female parasite had a length of 6 mm, a width of 0.34 mm. Oesophagus length was 0.26 mm (Figure 1A) and its width was 0.24 mm and a tail length of 0.14 mm (Figure 1B). The male parasites were 5.5 (5-6) mm long and 0.25 (0.24-0.26) mm wide. The bursa copulatrix of the male parasite was well developed and has four ribs, two ventral and two lateral, and a long dorsal rib (Figure 1C). The spicules were equal and 0.64 (0.63-0.65) mm long (Figure 1D) with transverse lines on them (Figure 1E). Gubernaculum was measured as 0.85 (0.84-0.86) mm (Figure 1D). A gubernaculum is present in all species but not in *T. subcrenatus* (4). Besides, there were button-like cuticular ornaments (Figure 1F) on the parasite. The distance of these ornaments from the front end was 0.72 mm. Also, papillae-like structures were noticed at 0.2 mm after the end of the oesophagus.



**Figure 1.** *Troglostrongylus brevior*. A- Anterior extremity, lateral view; note the inflated cuticle and the excretory pore (EP), B- Tail of female, lateral view; note anus (A), C- Bursa of male and bursal rays, lateral view. D- Bursa and gubernaculum (G) of male, lateral view, E- Spicules with transverse lines, F- Cuticular ornaments (CO), Scale bar =100  $\mu$ m

## DISCUSSION

Nematodes in the genus *Troglostrongylus* have been considered a parasite of wild felids such as pars cat, short-tailed wild cat, Canadian lynx, Eurasian lynx, leopard, tiger, European and Ethiopian wild cats (5). In domestic cats, after the first report (6), the infection was reported from the Islands of Greece (3,7,8), Bulgaria (9), and Italy (3,8).

Compared with *T. brevior*, *T. subcrenatus* and *A. abstrusus*, it can be distinguished due to body size, measurement differences in its morphological features and anatomical localization in the upper respiratory tract (bronchi and bronchioles).

Since Troglstrongyloids can reach the infective stage in many types of intermediate hosts and under different climatic conditions, they may have a wider potential distribution than is currently thought. *T. brevior* has also been isolated from domestic cats in regions where wild cat populations live close to urban life (10). In addition, parasites have been reported in areas where the natural host responsible for the spread of *Troglostrongylus* infection is not present (6,11). In areas where the parasite is present, it may be a carrier for cats travelling with the owners of areas where the parasite is not seen, as well as potential spread through the paratenic intermediate host movements (11). Studies have shown that the larvae of *T. brevior* can pass to kittens through lactation from the mother. There are two different opinions about this type of contamination. Firstly, the larvae that are inhibited in the mother cat before pregnancy can be activated by suppression of the immune system with pregnancy and lactation. In this case, infective larvae can migrate to the mammary glands. Another thought is that it needs more hunting to meet the increased protein need of the pregnant cat. During this hunting, infectious larvae are removed from the body by taking the paratenic intermediate hosts (7). In this context, cats can have parasites from the mother after birth, even if they are not in any external life.

*Troglostrongylus brevior* larvae are resistant to environmental conditions. It develops at an infective stage at low temperatures (40 days at 4-8 °C), but *A. abstrusus* larvae could not become infective when kept in the same environmental conditions for 7 months. *Troglostrongylus brevior* larvae become infective in 8 days under optimal conditions (22-27 °C). This period is the shortest known development period among other metastrongyloid parasites (2). This means that *T. brevior* will potentially spread faster in cats than *A. abstrusus* and affect a larger population.

Since troglstrongylosis does not have a specific clinical symptom, it can be confused with many upper respiratory diseases. The most common clinical symptoms in cats with troglstrongylosis are cough, shortness of breath and tachypnea (3,12-14). It can also be seen in non-disease-specific symptoms such as anorexia, hyporexia, hyperthermia, hypothermia, dehydration, and weakness (12,13). In our case, symptoms that may be confused with other patients such as weakness, vomiting and dehydration were observed.

Clinical diagnosis is almost impossible since no specific results can be obtained from clinical diagnostic methods. These clinical, laboratory and radiographic diagnostic methods only work to diagnose lower respiratory. Blood biochemical analysis does not make a significant difference for *Troglostrongylus*. Complete blood count levels are within normal limits for most of the cats affected by *T. brevior* (7).

As a result, in cats with complaints related to the respiratory system, veterinarians do not ignore parasitic factors, and at least, during the first stool examination by the Baermann method or bronchoalveolar lavage or swab method, 1<sup>st</sup> larva control (5) benefit is seen. For therapeutic purposes, spot-on eprinomectin is treating cat troglostrongylosis (15).

## CONCLUSION

There is no reported study about the prevalence of *T. brevior* in cats in Turkey. Physicians should also perform parasitic examinations in cats with respiratory problems, at least through the Baermann method, but they are not routinely performed in small animal practice in Turkey.

### \* Ethics

**Informed Consent:** Patient consent, as material from a dead cat was sent to us for diagnostic purposes form is not needed.

**Peer-review:** Internally peer-reviewed.

### \* Authorship Contributions

Concept: Ş.U., A.T.G., Design: Ş.U., Ö.B., E.B.G.T., A.T.G., Data Collection or Processing: Ş.U., Ö.B., E.B.G.T., A.T.G., Analysis or Interpretation: Ş.U., Ö.B., E.B.G.T., A.T.G., Literature Search: Ş.U., Ö.B., E.B.G.T., Writing: Ş.U., Ö.B.

**Conflict of Interest:** No conflict of interest was declared by the authors.

**Financial Disclosure:** The authors declared that this study received no financial support.

## REFERENCES

- Traversa D, Di Cesare A. Diagnosis and management of lungworm infections in cats: Cornerstones, dilemmas and new avenues. *J Feline Med Surg* 2016; 18: 7-20.
- Gerichter CB. Studies on the nematodes parasitic in the lungs of Felidae in Palestine. *Parasitol* 1949; 39: 251-62.
- Brianti E, Gaglio G, Giannetto S, Annoscia G, Latrofa MS, Dantas-Torres F, et al. *Troglostrongylus brevior* and *Troglostrongylus subcrenatus* (Strongylida: Crenosomatidae) as agents of broncho-pulmonary infestation in domestic cats. *Parasit Vectors* 2012; 5: 178.
- Brianti E, Giannetto S, Dantas-Torres F, Otranto D. Lungworms of the genus *Troglostrongylus* (Strongylida: Crenosomatidae): neglected parasites for domestic cats. *Vet Parasitol* 2014; 202: 104-12.
- Crisi PE, Di Cesare A, Boari A. Feline troglostrongylosis: current epizootiology, clinical features, and therapeutic options. *Front Vet Sci* 2018; 5:126.
- Jefferies R, Vrhovec MG, Wallner N, Catalan DR. *Aelurostrongylus abstrusus* and *Troglostrongylus* sp. (Nematoda: Metastrongyloidea) infections in cats inhabiting Ibiza, Spain. *Vet Parasitol* 2010; 173: 344-8.
- Brianti E, Gaglio G, Napoli E, Falsone L, Giannetto S, Latrofa MS, et al. Evidence for direct transmission of the cat lungworm *Troglostrongylus brevior* (Strongylida: Crenosomatidae). *Parasitology* 2013; 140: 821-4.
- Tamponi C, Varcasia A, Pinna S, Melis E, Melosu V, Zidda A, et al. Endoparasites detected in faecal samples from dogs and cats referred for routine clinical visit in Sardinia, Italy. *Vet Parasitol Reg Stud Reports* 2017; 10: 13-7.
- Giannelli A, Capelli G, Joachim A, Hinney B, Losson B, Kirkova Z, et al. Lungworms and gastrointestinal parasites of domestic cats: a European perspective. *Int J Parasitol* 2017; 47: 517-28.
- Di Cesare A, Veronesi F, Traversa D. Felid Lungworms and Heartworms in Italy: More Questions than Answers? *Trends Parasitol* 2015; 31: 665-75.
- Diakou A, Di Cesare A, Barros LA, Morelli S, Halos L, Beugnet F, et al. Occurrence of *Aelurostrongylus abstrusus* and *Troglostrongylus brevior* in domestic cats in Greece. *Parasit Vectors* 2015; 8: 590.
- Crisi PE, Traversa D, Di Cesare A, Luciani A, Civitella C, Santori D, et al. Irreversible pulmonary hypertension associated with *Troglostrongylus brevior* infection in a kitten. *Res Vet Sci* 2015; 102: 223-7.
- Diakou A, Di Cesare A, Aeriniotaki T, Traversa D. First report of *Troglostrongylus brevior* in a kitten in Greece. *Parasitol Res* 2014; 113: 3895-8.
- Giannelli A, Passantino G, Ramos RA, Lo Presti G, Lia RP, Brianti E, et al. Pathological and histological findings associated with the feline lungworm *Troglostrongylus brevior*. *Vet Parasitol* 2014; 204: 416-9.
- Giannelli A, Brianti E, Varcasia A, Colella V, Tamponi C, Di Paola G, et al. Efficacy of Broadline® spot-on against *Aelurostrongylus abstrusus* and *Troglostrongylus brevior* lungworms in naturally infected cats from Italy. *Vet Parasitol* 2015; 209: 273-7.