

# Determination of *Aelurostrongylus abstrusus* Prevalence and Risk Factors in Cats from Balıkesir

## Balıkesir İlindeki Kedilerde *Aelurostrongylus abstrusus* Prevalansı ve Risk Faktörlerinin Belirlenmesi

İlayda Yıldırım<sup>1</sup>, Buse Öztürk<sup>2</sup>, Damla Ekin Solmaz<sup>3</sup>, Ersoy Baydar<sup>3</sup>, Uğur Aydoğdu<sup>3</sup>

<sup>1</sup>Kastamonu University Faculty of Veterinary Medicine, Department of Pathology, Kastamonu, Türkiye

<sup>2</sup>Balıkesir University Faculty of Veterinary Medicine, Department of Obstetrics, Gynecology and Reproduction, Balıkesir, Türkiye

<sup>3</sup>Balıkesir University Faculty of Veterinary Medicine, Department of Internal Medicine, Balıkesir, Türkiye

Cite this article as: Yıldırım İ, Öztürk B, Solmaz DE, Baydar E, Aydoğdu U. Determination of *Aelurostrongylus abstrusus* Prevalence and Risk Factors in Cats from Balıkesir. Türkiye Parazit Derg 2023;47(2):78-82.

### ABSTRACT

**Objective:** The lungworms are nematodes that live as parasites in cat lungs. It is reported that the most common lungworm is *Aelurostrongylus abstrusus* in cats, and also *Capillaria aerophila* is observed. The lungworms can cause infection of the lower respiratory tract, often resulting in bronchitis and pneumonia. In this study, it was aimed to determine the prevalence and risk factors of *A. abstrusus* in cats in the Balıkesir province.

**Methods:** This study was carried out on 100 cats in Balıkesir province. Fresh stool samples (>15 g) were collected for detection of lungworms after recorded all cat information (breed, age, sex, etc.). Parasite-specific L1 forms were determined from the stool samples by the Baerman-Wetzel technique.

**Results:** *A. abstrusus* L1's were found in 5 of the 100 stool samples examined. While symptoms of respiratory system disease were observed in 2 of the cats with lungworm, no clinical finding of the presence of parasites was found in 3 of them.

**Conclusion:** *A. abstrusus* was observed at a level of 5% in this first prevalence study in cats in Balıkesir province.

**Keywords:** *Aelurostrongylus abstrusus*, clinical symptoms, diagnosis, prevalence

### ÖZ

**Amaç:** Akciğer kurtları, kedilerin akciğerlerinde parazit olarak yaşayan nematodlardır. Kedilerde en sık görülen akciğer kurdunun *Aelurostrongylus abstrusus* olduğu ve ayrıca *Capillaria aerophila*'nın görüldüğü bildirilmektedir. Akciğer kurtları, alt solunum yollarında enfeksiyona neden olarak sıklıkla bronşit ve zatürreye neden olabilir. Bu çalışmada, Balıkesir ilindeki kedilerde *A. abstrusus* prevalansının ve risk faktörlerinin belirlenmesi amaçlanmıştır.

**Yöntemler:** Bu çalışma Balıkesir ilinde 100 kedi üzerinde gerçekleştirilmiştir. Tüm kedi bilgileri (cins, yaş, cinsiyet vb.) kaydedildikten sonra akciğer nematodlarının tespiti için taze dışkı örnekleri (>15 g) toplanmıştır. Dışkı örneklerinde Baerman-Wetzel tekniği ile parazite özgü L1 formları aranmıştır.

**Bulgular:** İncelenen 100 dışkı örneğinin 5'inde *A. abstrusus*'a ait L1'ler bulundu. *A. abstrusus* larvası tespit edilen kedilerin 2'sinde solunum sistemi hastalığı belirtileri görülürken, 3'ünde parazit varlığına dair klinik bulguya rastlanmadı.

**Sonuç:** Balıkesir ilindeki kedilerde yapılan bu ilk prevalans çalışmasında *A. abstrusus* %5 düzeyinde gözlenmiştir.

**Anahtar Kelimeler:** *Aelurostrongylus abstrusus*, klinik semptomlar, teşhis, yaygınlık

### INTRODUCTION

Cat lungworms infect various parts of the respiratory system of domestic and wild felines (1). The nematode species in this group include members of the Metastrongyloidea superfamily, which are

characterized by an indirect life cycle and require intermediate (i.e., snails or slugs) and paratenic (i.e., amphibians, birds, reptiles, and rodents) hosts for their transmission (2). While *Aelurostrongylus abstrusus* (Strongylida: Angiostrongylidae) is considered the

Received/Geliş Tarihi: 09.09.2022 Accepted/Kabul Tarihi: 05.11.2022

Address for Correspondence/Yazar Adresi: İlayda Yıldırım, Kastamonu University Faculty of Veterinary Medicine, Department of Pathology, Kastamonu, Türkiye

Phone/Tel: +90 531 728 10 93 E-mail/E-Posta: ilaydayildirim@kastamonu.edu.tr ORCID ID: orcid.org/0000-0001-5021-3088

©Copyright 2023 Turkish Society for Parasitology - Available online at www.turkiyeparazitderg.org

This article is distributed under the terms of the Creative Commons Attribution-NonCommercial (CC BY-NC-ND) 4.0 International License.

main species infecting domestic cats, other metastrongyloids such as *Troglostrongylus brevior* (Strongylida: Crenosomatidae) and *Oslerus rostratus* (syn. *Anafilaroides rostratus*) (Strongylida: Filar) have long been considered of minimal importance (3,4). Although publications on *Trongylostrongylus* species in cats have increased in recent years, *A. abstrusus* is in the first place among the parasitic agents that cause respiratory tract infections (5). *A. abstrusus*, uses various snails and slugs as intermediate hosts. Birds, rodents, frogs, and lizards are carrier hosts. The development of the parasite is completed by the cat's acquisition of intermediate or carrier hosts (6). *Capillaria aerophila*, another of the lungworms, shows direct growth. Cats become infected by ingesting stools containing *C. aerophila* eggs. The agents are located in the lung parenchyma, bronchioles, and alveoli of the cats, which are the definitive hosts, and occasionally in the pulmonary arteries (7). Although symptoms such as difficulty breathing, coughing after movement, and runny nose can be seen in infected cats, death can only be seen in very severe infections since it is a non-pathogenic factor (8). Diagnosis can be made by stool examination in live cats. The most reliable method is the Baermann-Wetzel method in diagnosis. In addition, can use the flotation method to determine the eggs. With these methods, the larvae and eggs of parasites are detected. The Baermann-Wetzel method is based on collecting and examining water-loving larvae in a narrow area by passing into the water.

Lungworm infections are found in many parts of the world. The prevalence of lungworm infection varies between regions. It has been recorded in almost all European countries, in Australia and the Americas, and occasionally in Asia and Africa. The presence of *A. abstrusus* has been reported as 0.38-50% in cats in European countries and clinical cases in Belgium, France, Ireland, Norway, Poland and Türkiye (9). The first report about the presence of *A. abstrusus* in Türkiye was reported by Oytun (6). Even though case reports related to *A. abstrusus* in Türkiye (10-15) were made, no prevalence studies were found.

This study, it was aimed to determine the prevalence of *A. abstrusus* in cats in Balıkesir province. While studies on the prevalence of lungworms in cats have been carried out in many European countries, it is thought that there is a deficiency in this regard in Balıkesir. For this reason, determining the prevalence of lungworms in cats will provide information on this subject. In this context, revealed the prevalence of *A. abstrusus* was for the first time in Türkiye.

## METHODS

The study was designed to include indoor and outdoor, and was conducted on 100 cats living in shelters and privately owned properties in the Balıkesir province. Of the cats, 54 were owned and not connected to the outside environment, 13 were owned but connected to the external environment, and 33 were in the shelter environment. A total of 100 cats aged between 2 and 168 months in the same city centre and rural were analysed. While 40 of the cats included in the study were female and 27 were male, the records of 33 in the shelter could not be reached. Because the fecal samples of the cats shelters have been received after the cats are mass-released to a large area. However, the estimated ages have been registered as under 1 year of age and over, considering the time they stayed in the shelters. The examined cats had 4 Scottish Fold, 1 British Shorthair, 1 Angora, 5 Siamese, 2 Persian, and 87

Tabby and Crossbreeds. In addition, it was determined that 54 of them lived in the home environment. 46 cats were in contact with the outside environment or in shelters (Table 1). Thirty-three of the 46 cats in contact with the outdoors were in the same shelter. After all cat information (breed, age, sex, etc.) was recorded (Table 1), fresh fecal samples (>15 g) for detection of *A. abstrusus* were taken directly from the cages in which the animals were housed and collected in individual sterile plastic containers. Collected faeces were kept at 4 °C and examined as soon as possible (16). Stool samples were examined using the Baerman Wetzel technique to isolate first stage larvae (L1). A sample was considered positive when at least one L1 was identified. Specific morphological and morphometric identification of isolated *A. abstrusus* L1's and differentiation from L1's of other metastrongyloids was achieved by microscopic examination. L1 with the tails's characteristic notch and S-shaped tip was evaluated as *A. abstrusus*. Thorax radiographs were taken following the permission of their owners in 2 cats whose stools were found to contain parasite larvae. In addition, as a single dose applied antiparasitic treatment to 2 of the infected cats and showed symptoms, with a topical formulation (Brodline, Boehringer, New Zealand) containing Fipronil 74.7 mg/(S)-methoprene 90.0 mg/eprinomectin 3.60 mg/and praziquantel 74.7 mg.

## Statistical Analysis

In the statistical analysis of the study, descriptive statistics were given for the variables. Variables are expressed as frequency (percentage). The chi-square test was applied to the importance of categorical variables. Analyzes were performed using SPSS Version 22. A value of  $p < 0.05$  was considered significant.

**Table 1.** The positivity rates of *A. abstrusus* according to various variables in the cats examined in this study

| Variables                            | Animals examined | Animals positive | P                  |
|--------------------------------------|------------------|------------------|--------------------|
| <b>Sex</b>                           |                  |                  | *                  |
| Male                                 | 27               | 0                |                    |
| Female                               | 40               | 2                |                    |
| No record                            | 33               | 3                |                    |
| <b>Age</b>                           |                  |                  | 0.208 <sup>a</sup> |
| Over 1 year old                      | 34               | 3                |                    |
| Less than 1 year old                 | 66               | 2                |                    |
| <b>Habitat</b>                       |                  |                  | 0.519 <sup>a</sup> |
| Indoor                               | 54               | 2                |                    |
| Outdoor (shelter and outdoor access) | 46               | 3                |                    |
| <b>Antiparasitic therapy</b>         |                  |                  | 0.100 <sup>a</sup> |
| Yes                                  | 61               | 0                |                    |
| No                                   | 39               | 5                |                    |
| <b>Symptoms</b>                      |                  |                  | **                 |
| Yes                                  | 11               | 2                |                    |
| No                                   | 89               | 3                |                    |

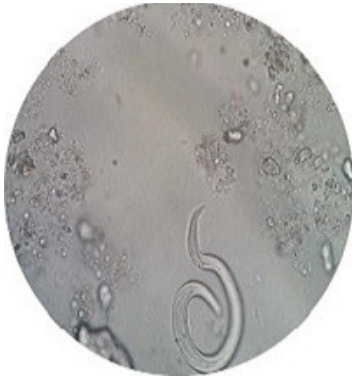<sup>a</sup>Chi-square significance level, chi-square test could not be performed because the gender of the cats in the shelter could not be determined. <sup>\*\*</sup>chi-square test for symptoms has not been evaluated

## RESULTS

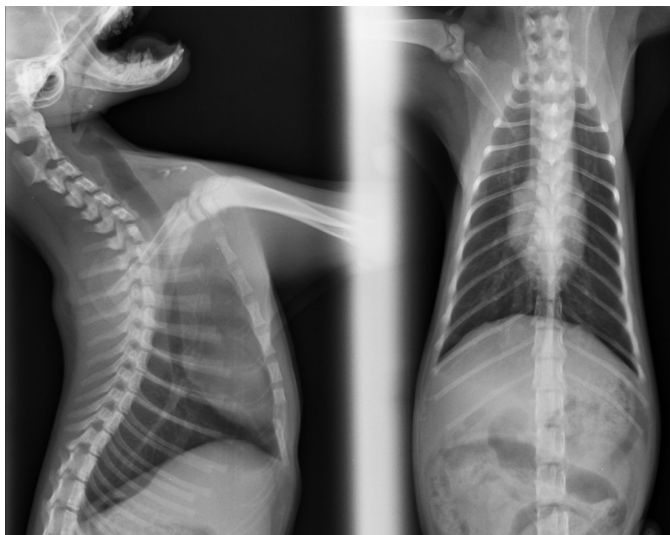
Of the 100 cats included in the study, 11 had clinical symptoms such as pulmonary wheezing, coughing, and respiratory distress. However, these clinical symptoms were not observed in 89 of them. Sixty-one cats previously were treated with antiparasitic, but 39 were not treated with antiparasitic.

Specific and morphometric identification of 5 of the 100 cats included in the study and *A. abstrusus* L1's were determined by microscopic examination. In addition, with the specific morphological identification of *A. abstrusus* L1's, it was possible to distinguish them from L1's of other metastrongyloids. L1 with the tails's characteristic notch and S-shaped tip was evaluated as *A. abstrusus* (Figure 1).

Two of these five 5 cats were female and they lived in a different home environment from each other, but they were communicating with the outside environment. Two of the 5 cats had clinical symptoms such as pulmonary wheezing, coughing and respiratory distress, but these clinical symptoms were not observed in 3 of them. Considering the history of the 5 positive cats and the 2 owner cats included in this group, it was learned that they did not apply antiparasitic treatment. Radiographic images (Figure 2) were obtained from 2 of the cats in which larvae were detected in their stools. While detected a mild bronchiole pattern in one of



**Figure 1.** Appearance of Baermann-Wetzel sediment in cat of *A. abstrusus* first stage larvae (L1)



**Figure 2.** Thoracic radiographs of infected cat with *A. abstrusus*

the cats, no significant finding was found in the other. No parasite larvae were found at the fecal examination after 2 weeks of the cat being supplied with antiparasite treatment. At the same time, these cats did not show clinical symptoms after 2 weeks.

## DISCUSSION

*Aelurostrongylus abstrusus* is the most common lungworm of domestic and wild felines and is found in many parts of the world, including Europe, the United States of America, South America, and Australia (1). This parasite has a significant impact on the health and welfare of cats. Moreover, regional endemism and geographic expansion are observed throughout Europe (5,17). In addition to *A. abstrusus*, other metastrongyloids have been detected in cats lungs in recent studies, such as *Troglostrongylus brevior* (Crenosomatidae) and *Oslerus rostratus* (Filaroididae) and the trichurid *Eucoleus aerophilus* (syn. *Capillaria aerophila*) (1,18). Biological and epidemiological factors appear to increase the risk of infection in cats in certain parts of the world, although some are yet to be confirmed (14-17). The prevalence of lungworm infection in many parts of the world varies considerably between the examined regions. Global prevalence rates range from 50% in free-range cats in Albania (19) to 1% in the mixed cat population in Spain (20). The first report about the presence of *A. abstrusus* in Türkiye was reported by Oytun (6). It was reported by Burgu and Sarimehmetoğlu (8) in 2004 that *A. abstrusus* was detected in two cats. Gökpinar and Yildiz (16), examined the lesions of *A. abstrusus* in the cat lung using scanning electron microscopy. In 2021, Baydar and Kaya (10), detected *A. abstrusus* larvae in a two-month-old cat who had been suffering from respiratory distress for fifteen days in Balıkesir. *A. abstrusus* has a cosmopolitan distribution and has been recorded in nearly all countries in Europe, frequently in Australia and the Americas, and occasionally in Asia and Africa. The presence of *A. abstrusus* has been reported in cats in European countries, 39.7-50% in Albania, 1.8-22.4% in Italy, 0.38-22% in Croatia, 0.5-15.3% in Germany, 3.6% in Great Britain 10.6, 2.6% in the Netherlands, 14.5% in Hungary, 17.4% in Portugal, 5.6% in Romania, 1% in Spain, and clinical cases in Belgium, France, Ireland, Norway, Poland and Türkiye (5). A recent study in England, it was reported that *A. abstrusus* was observed at a rate of 1.7% (21). In this study, it was determined that *A. abstrusus* was observed at a rate of 5% in cats in the Balıkesir province. This result was similar to the rates reported in Europe. However, since the results only include cats in the Balıkesir province, they do not provide information about the prevalence of *A. abstrusus* throughout Türkiye. Recently, the number of cases has been increased in various countries and in the frequency of detection by clinicians (22). This situation may be critical for us to know the general prevalence and to reveal the risk factors to determine the prevalence of lungworms such as *A. abstrusus*. Publications on *Trichostrongylus* species in cats have increased in recent years. In 2020, a case report about *T. brevior* was published in Balıkesir province (23). But *A. abstrusus* is in the first place among the parasitic agents that cause respiratory tract infections. Although cats infected with *A. abstrusus* may experience chronic wasting, coughing, difficulty breathing, pulmonary wheezing, and other signs of lower respiratory disease, asymptomatic cases can also occur with large numbers of larvae in the stools. Diagnosis and treatment delays can lead to severe lesions and even death in infected cats (5,14). Yildiz et al.



(24), reported that hypoventilation and respiratory acidosis were observed in cats with *A. abstrusus*. In this study, while clinical findings were observed in 2 of 5 cats, it was not observed in 3 of them. This supports the existence of cases that scatter larvae and show no symptoms.

It is stated that the access of cats to the outside causes an increased risk of infection (14,17,19). Elsheikha et al. (21), highlighted in their study that keeping cats indoors provides significant protection against infection and that infection is much more common in cats with outside access. In contrast, the same study found no significant difference between cats with outside access and stray cats, possibly due to the small number of cats in these categories (21). In our study, 3 of the 5 positive cats were living in the shelter, while 2 were indoors. However, both of the positive indoor cats were adopted from the street. These results support the view that being cared for in outdoor by cats increases the risk of infection. Although the chi-square test results were insignificant, it was evaluated that the habitat might be effective in the transmission of the parasite due to the fact that 5 cats were connected to the outside, and it was thought that the insignificant results might be related to the low number of cats in the study.

Elsheikha et al. (21), showed that there is no relationship between the history of antiparasitic treatment and the risk of infection. Although antiparasitic therapy is not associated with a significant reduction in the risk of infection, therapy is still an important factor influencing the frequency of infection with lungworm in cats. Whether repeated monthly treatments would increase the efficacy of the product in cats infected by *A. abstrusus* should be defined (25). In this study determined that there was no routine antiparasitic treatment in any of the infected cats. According to the chi-square ( $p=0.100$ ) test results, it was determined that there was no significant relationship between the application of antiparasitic treatment and the risk of parasites.

Various drugs (fenbendazole and ivermectin) are used for the treatment of lungworms (24). A topical formulation containing fipronil, (S)-methoprene, eprinomectin, and praziquantel have been evaluated for efficacy against larvae and adult *A. abstrusus* in experimentally infected cats and are licensed for the treatment of *A. abstrusus* in some countries (26). In this study, applied antiparasitic treatment to 2 of the infected cats and showed symptoms, with a topical formulation (Brodline, Boehringer, New Zealand) containing Fipronil, (S)-methoprene, eprinomectin and praziquantel.

Naturally infected symptomatic cats may also show a mix of bronchial and interstitial pulmonary patterns on thoracic radiographs (27). In this study, radiographic findings of only 2 cats with aelurostrongylosis could be evaluated, while could not be perform radiographic examination of the other 3 positive cats. When evaluated the radiographic findings of 2 infected cats, a mild bronchial pattern was detected in 1, while no significant finding was found in the other.

In conclusion, it was determined that *A. abstrusus* was observed at a rate of 5% in this first prevalence study in cats in Balıkesir province and may be present without any clinical symptoms. In addition, it was concluded that the presence of lungworms in cats with pneumonia should also be considered.

### Study Limitations

Molecular research could not be done in this study due to lack of budget. Since some cats were in the shelter environment, their

gender could not be determined. Therefore, statistical analysis could not be performed.

## CONCLUSION

In this study, the stools of 100 cats in Balıkesir were evaluated by the Baermann-Wetzel method for diagnosing of *A. abstrusus* larvae. It is the first prevalence study conducted in Balıkesir for this agent, and *A. abstrusus* larvae at the level of 5% were detected microscopically. At the same time, observed respiratory system clinical symptoms in a few of the cats infected with the agent, and the cats showing these symptoms were examined radiographically. We believe that should evaluate clinical symptoms and radiography in addition to the Baermann-Wetzel diagnostic method for *A. abstrusus*. Antiparasitic treatment was applied to cats with clinical findings, and this treatment successfully eliminated the agent. Considering the history of five cats with positive results, it was determined that they were in contact with the street. This study showed that contacting cats on the street with each other is essential in terms of the risk factors of *A. abstrusus*.

### \* Acknowledgment

The authors thank Assistant Professor Mehmet Özüüçü (Balıkesir University, Faculty of Veterinary Medicine) for the parasitological evaluation.

### \* Ethics

**Ethics Committee Approval:** This study was approved by the Balıkesir University Animal Experiments Local Ethics Committee (2019-11-4).

**Informed Consent:** Not necessary.

**Peer-review:** Internally and externally peer-reviewed.

### \* Authorship Contributions

Surgical and Medical Practices: İ.Y., B.Ö., D.E.S., Concept: E.B., U.A., Design: D.E.S., E.B., U.A., Data Collection or Processing: İ.Y., B.Ö., D.E.S., Analysis or Interpretation: İ.Y., D.E.S., E.B., Literature Search: E.B., U.A., Writing: D.E.S., E.B., U.A.

**Conflict of Interest:** No conflict of interest was declared by the authors.

**Financial Disclosure:** This study was supported by the Scientific and Technological Research Council of Türkiye (TUBITAK BİDEB, 2209/A).

## REFERENCES

- Giannelli A, Capelli G, Joachim A, Hinney B, Losson B, Kirkova Z, et al. Lungworms and gastrointestinal parasites of domestic cats: a European perspective. *Int J Parasitol* 2017; 47: 517-28.
- Bowman DD, Lynn R, Eberhard M. *Parasitology for Veterinarians*. Saunders Company, USA: Philadelphia; 1995.
- Losonsky JM, Thrall DE, Prestwood AK. Radiographic evaluation of pulmonary abnormalities after *Aelurostrongylus abstrusus* inoculation in cats. *Am J Vet Res* 1983; 44: 478-82.
- Gürler AT. Türkiye'de evcil hayvanlarda bulunan solunum sistemi helmintleri [Check list of the helminths in the respiratory system of domesticated animals in Turkey]. *Türkiye Parazitoloj Derg* 2006; 30: 194-9.
- Elsheikha HM, Schnyder M, Traversa D, Di Cesare A, Wright I, Lacher DW. Updates on feline aelurostrongylosis and research priorities for the next decade. *Parasit Vectors* 2016; 9: 389.

6. Oytun H. Genel Parazitoloji ve Helmintoloji. 2. Baskı. Ankara: Ankara Üniversitesi Veteriner Fakültesi Yayınları 1961; 55: 650-1.
7. Tüzer E, Toparlak M, Gargili A, Keleş V, Esatgil MU. A case of *Aelurostrongylus abstrusus* infection in a cat in Istanbul, Turkey and its treatment with moxidectin and levamisole. *Turk J Vet Anim Sci* 2002; 26: 411-4.
8. Burgu A, Sarimehmetoğlu O. *Aelurostrongylus abstrusus* infection in two cats. *Vet Rec* 2004; 154: 602-4.
9. Atasever A, Yazar S. Immun Sistemi Baskılanmış Bir Kedide *Aelurostrongylus abstrusus* Pnömonisi [Aelurostrongylus abstrusus pneumonia in an immunosuppressed cat]. *Türkiye Parazitol Derg* 2009; 33: 89-91.
10. Baydar E, Kaya F. *Aelurostrongylus abstrusus* infection and radiographic findings in a kitten. *Kocatepe Vet J* 2021; 14: 278-83.
11. Gericht CB. Studies on the nematodes parasitic in the lungs of Felidae in Palestine. *Parasitology* 1949; 39: 251-62.
12. Giannelli A, Ramos RA, Annoscia G, Di Cesare A, Colella V, Brianti E, et al. Development of the feline lungworms *Aelurostrongylus abstrusus* and *Troglostrongylus brevior* in *Helix aspersa* snails. *Parasitology* 2014; 141: 563-9.
13. Brianti E, Giannetto S, Dantas-Torres F, Otranto D. Lungworms of the genus *Troglostrongylus* (Strongylida: Crenosomatidae): neglected parasites for domestic cats. *Vet Parasitol* 2014; 202: 104-12.
14. Hansen AP, Skarbye LK, Vinther LM, Willesen JL, Pipper CB, Olsen CS, et al. Occurrence and clinical significance of *Aelurostrongylus abstrusus* and other endoparasites in Danish cats. *Vet Parasitol* 2017; 234: 31-9.
15. Beugnet F, Bourdeau P, Chalvet-Monfray K, Cozma V, Farkas R, Guillot J, et al. Parasites of domestic owned cats in Europe: co-infestations and risk factors. *Parasit Vectors* 2014; 7: 291.
16. Gökpınar S, Yıldız K. Çeşitli Sıcaklık Derecelerinin Kedi Dişkisindeki *Aelurostrongylus Abstrusus* 1. Dönem Larvasının Canlılığına Etkisi [The effect of different temperatures on viability of *Aelurostrongylus abstrusus* first stage larvae in faeces of cats]. *Türkiye Parazitol Derg* 2010; 34: 102-5.
17. Traversa D, Guglielmini C. Feline aelurostrongylosis and canine angiostrongylosis: a challenging diagnosis for two emerging verminous pneumonia infections. *Vet Parasitol* 2008; 157: 163-74.
18. Addie D, Belák S, Boucraut-Baralon C, Egberink H, Frymus T, Gruffydd-Jones T, et al. Feline infectious peritonitis. ABCD guidelines on prevention and management. *J Feline Med Surg* 2009; 11: 594-604.
19. Knaus M, Kusi I, Rapti D, Xhaxhiu D, Winter R, Visser M, et al. Endoparasites of cats from the Tirana area and the first report on *Aelurostrongylus abstrusus* (Railliet, 1898) in Albania. *Wien Klin Wochenschr* 2011; 123(Suppl 1): 31-5.
20. Miró G, Montoya A, Jiménez S, Frisuelos C, Mateo M, Fuentes I. Prevalence of antibodies to *Toxoplasma gondii* and intestinal parasites in stray, farm and household cats in Spain. *Vet Parasitol* 2004; 126: 249-55.
21. Elsheikha HM, Wright I, Wang B, Schaper R. Prevalence of feline lungworm *Aelurostrongylus abstrusus* in England. *Vet Parasitol Reg Stud Reports* 2019; 16: 100271.
22. Gunn-Moore D, Elsheikha HM. Current status of feline lungworm in the UK. *Vet Rec* 2018; 182: 113-4.
23. Umur Ş, Barılı Ö, Gencay Topçu EB, Gürler AT. First Report of a *Troglostrongylus brevior* Case in a Domestic Cat in Turkey. *Türkiye Parazitol Derg* 2020; 44: 176-8.
24. Yıldız K, Duru SY, Gokpınar S. Alteration in blood gases in cats naturally infected with *Aelurostrongylus abstrusus*. *J Small Anim Pract* 2011; 52: 376-9.
25. Giannelli A, Brianti E, Varcasia A, Colella V, Tamponi C, Di Paola G, et al. Efficacy of Broadline® spot-on against *Aelurostrongylus abstrusus* and *Troglostrongylus brevior* lungworms in naturally infected cats from Italy. *Vet Parasitol* 2015; 209: 273-7.
26. Knaus M, Chester ST, Rosentel J, Kühnert A, Rehbein S. Efficacy of a novel topical combination of fipronil, (S)-methoprene, eprinomectin and praziquantel against larval and adult stages of the cat lungworm, *Aelurostrongylus abstrusus*. *Vet Parasitol* 2014; 202: 64-8.
27. Dennler M, Bass DA, Gutierrez-Crespo B, Schnyder M, Guscetti F, Di Cesare A, et al. Thoracic computed tomography, angiographic computed tomography, and pathology findings in six cats experimentally infected with *Aelurostrongylus abstrusus*. *Vet Radiol Ultrasound* 2013; 54: 459-69.